Case Report | TORGJ | Volume 2 Issue 4 | December 2026

DOI: https://doi.org/10.64573/torgj2610005

The Operating Room Global Journal (TORGJ)

https://torgjournal.org/

ISSN: 3105-3262

Crossref

OPEN ACCESS

Outcomes of Multimodal Therapy for Bladder Neuroendocrine Carcinoma: A Case Series

Maaz Khan[1], Nasir Khan[2], Abdul Haseeb[1,3*] and Riaz Ahmed Khan[1]

[1] Department of Urology, Institute of Kidney Diseases Peshawar, Pakistan
[2] Department of Urology, Bacha Khan Medical Complex, Swabi, Pakistan
[3] The Operating Room Global (TORG)

***Corresponding Author:**
Dr. Abdul Haseeb
ahaseeb.dr@gmail.com

Declaration:

Authors' Contributions: MK and AH drafted the manuscript. RAK supervised the work, and NK critically reviewed the manuscript. All authors approved the final manuscript for publication.

Conflict of Interests: None

Funding: No funding received.

Article History:
Received: 06-10-2026
Accepted: 20-10-2026
Available Online: 22-11-2026

QR access this Article

ABSTRACT

Background: Muscle-invasive small cell neuroendocrine carcinoma (SNECUB) of the urinary bladder is a rare and very aggressive type of bladder cancer, and accounts for less than 1% of all bladder cancers

Case Presentation: All the three patients presented with painless hematuria, having no significant co morbid and no history of smoking or alcohol intake. There were no other significant associated complaints. Further details are given in individual case presentation.

Clinical Findings and Investigations: Clinical Findings among all the patients very unremarkable. All patients underwent Baseline and mandatory radiological investigations.

Intervention and Outcome: All the patients underwent cystoscopy and transurethral resection of bladder tumor, with subsequent histopathological assessment, immunohistochemical analysis and further management in the form of Neoadjuvant chemotherapy followed by Radical cystectomy with urinary diversion. All the patients were assessed with after one month and six-month post-surgery. There were no recurrences or any significant post-operative complication

Conclusion: Neoadjuvant cisplatin–etoposide chemotherapy followed by radical cystectomy offers the best chance for prolonged survival in localized SNECUB by exploiting the tumor's chemosensitivity and reducing metastatic risk. Despite the lack of standardized guidelines, current evidence supports this multimodal approach as the cornerstone of treatment. Future studies should evaluate optimized neoadjuvant regimens and the role of immunotherapy.

Keywords: *Urinary Bladder Tumor, Urinary Bladder Carcinoma, Neuroendocrine Tumor, Hematuria*

INTRODUCTION

Muscle-invasive small cell neuroendocrine carcinoma (SNECUB) of the urinary bladder is a rare and very aggressive type of bladder cancer, and accounts for less than 1% of all bladder cancers [1,2]. This malignancy is characterized by its neuroendocrine differentiation and typically presents with high-grade features, including rapid growth and early metastasis [1,2]. Clinical manifestations often include symptoms such as gross hematuria, dysuria, and urinary frequency [2]. Due to its aggressive nature and poor prognosis, early detection and aggressive management strategies are crucial for improving patient outcomes. Treatment approaches often involve a multidisciplinary approach, including surgery, chemotherapy, and radiotherapy, with chemotherapy regimens commonly involving cisplatin and etoposide [2,3]. Despite these efforts, the prognosis remains challenging due to the high recurrence rates and metastatic potential of this disease [1,3].

CASE PRESENTATION 1

A 75-year-old male patient with no known co-morbidities, presented with complaints of hematuria for the past 5 months. He had no history of smoking or chronic cystitis. He was physically active and fit for surgery with ECOG score of zero. Apart from baseline investigations, which were normal, an ultrasound KUB was done which showed thick-walled urinary bladder with about 44 x 36.6mm lobulated, soft echogenic solid lesion in the left posterolateral wall of the bladder, having minimal intralesional blood flow.

Furthermore, CT abdomen and pelvis with contrast was done which showed well-defined, lobulated lesion with heterogeneous enhancement, characterized by a soft tissue density along the base and left lateral wall of the bladder, measuring 5.4 x 2.0cm. Minimal perivesical fat stranding and no extra serosal extension was seen.

CT thorax with contrast was unremarkable with no evidence of metastases. Patient was counselled for cystoscopy and transurethral resection of bladder tumor (TURBT), resection of the tumor involving left posterior wall and base of the bladder was performed and histopathology report ordered. The results showed malignant neoplasm composed of atypical cells in a sheeted pattern with stippled chromatin and scant cytoplasm. Immunohistochemical stains were positive for synaptophysin and negative for GATA3. Based on the histopathology report, a diagnosis of high grade neuroendocrine small cell carcinoma with detrusor muscle invasion was made.

Bone scan did not show any skeletal metastases. A multidisciplinary meeting was scheduled in which decision was taken for the patient to undergo neoadjuvant chemotherapy (NC) followed by radical cystectomy (RC). A cisplatin and etoposide-based chemotherapy regimen was employed successfully without significant adverse effects, later followed by surgical removal of the bladder (radical cystectomy) combined with the removal of pelvic lymph nodes (pelvic lymphadenectomy) and the creation of a new pathway for urine to exit the body (urinary diversion) after a month. The post-operative specimen obtained was submitted for histopathology again, which confirmed clear surgical margins and no nodal involvement. This outcome highlights a notable response of SNECUB to neoadjuvant chemotherapy followed by radical cystectomy in our case.

CC-BY 4.0 Licensed

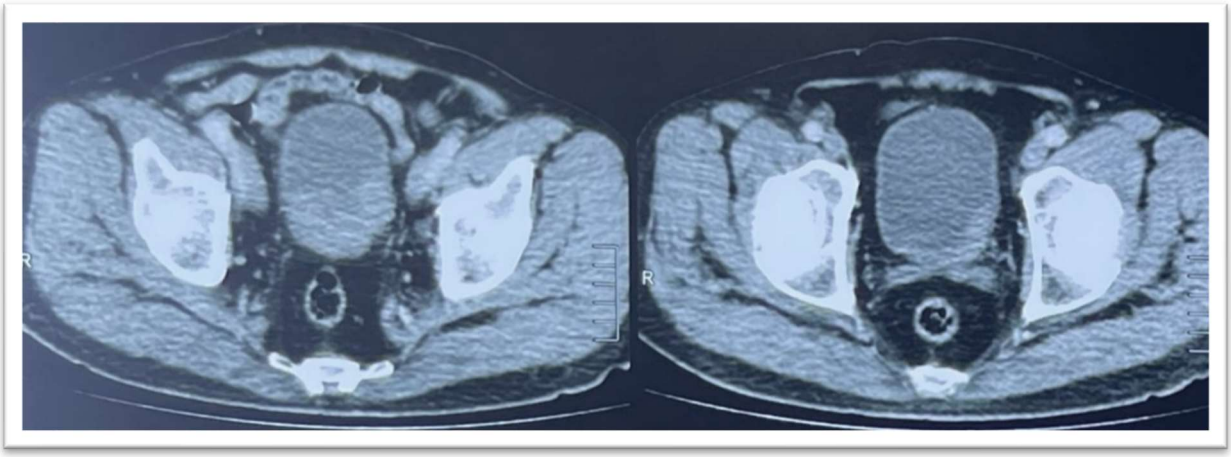

Figure 1 Axial view of contrast enhanced CT scan of abdomen and pelvis showing 5.4 x 2.0cm lesion along the base of bladder and left posterior wall as pointed by the red arrows.



Figure 2A Shows microscopic image of synaptophysin staining at 20x

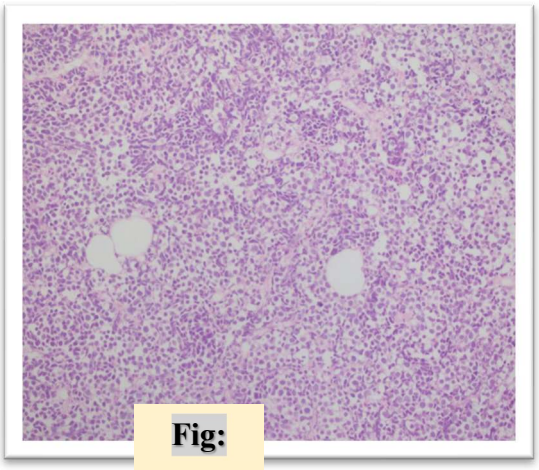

Figure 2B Shows microscopic image of H&E staining of tumor specimen at 20x

CASE PRESENTATION 2

A 67-year-old male presented with a one-year history of painless, intermittent hematuria. His past medical history was unremarkable, and he reported no tobacco or alcohol use. His performance status was excellent (ECOG 0). Initial workup included urinalysis, which revealed hematuria and pyuria. Notably, urine culture grew Streptococcus Bovis. Subsequent abdominal and pelvic ultrasound identified a heterogeneous bladder mass measuring 45mm x 16mm. Contrast-enhanced CT imaging further characterized the mass as an 8cm x 2cm bladder tumor involving the left vesico-ureteric junction, with infiltration into the perivesical fat and abutment of the left pelvic sidewall. There was no evidence of lymph node involvement or distant metastases on CT imaging.

Cystoscopy revealed a left lateral bladder mass involving the left ureteral orifice, extending to the posterior and anterior walls, and the bladder neck. TURBT was performed, and histopathological analysis confirmed a diagnosis of solid SNECUB, staged as at least pT2 (muscle invasive). Immunohistochemical staining was positive for cytokeratin, synaptophysin, CD-56, and P-63, consistent with neuroendocrine differentiation. A bone scan was unremarkable.

CC-BY 4.0 Licensed

Following multidisciplinary review, the patient underwent treatment with four cycles of neoadjuvant chemotherapy consisting of etoposide and cisplatin. He tolerated the chemotherapy well. Post-chemotherapy CT imaging demonstrated significant tumor regression, with no evidence of distant metastases.

Approximately one month after completing neoadjuvant chemotherapy, the patient underwent RC with pelvic lymphadenectomy and urinary diversion. Final pathology revealed clear surgical margins and no lymph node involvement. Follow-up CT scans at three and six months post-operatively showed no evidence of local recurrence or distant metastases. This case demonstrates a significant response of SNECUB to neoadjuvant chemotherapy (NC) followed by radical cystectomy (RC).

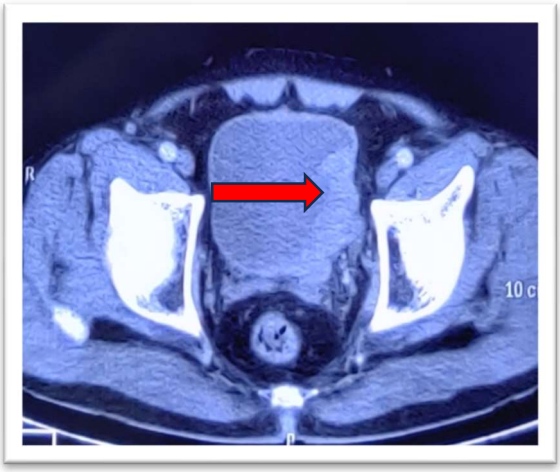

Figure 3 Show axial view of contrast enhanced CT scan of abdomen and pelvis showing, urinary bladder tumor measuring approximately 8cm x 2cm involving the left vesico-ureteric junction as pointed by the red arrow.

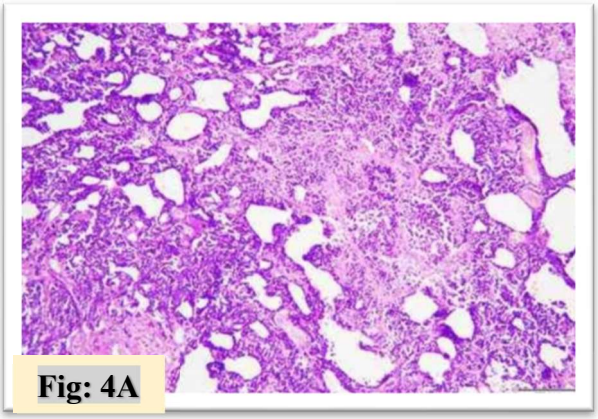

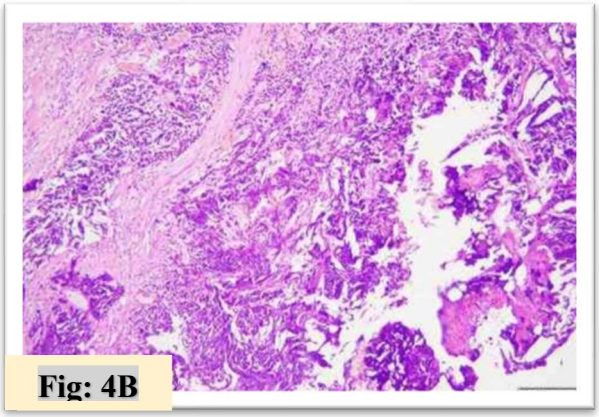

Figure 4 (A & B) Histological examination of the section reveals multiple fragments showing a malignant neoplasm arranged in sheets. The individual neoplastic cells show pleomorphic nuclei with molding of nuclear membranes and scant cytoplasm. Brisk atypical mitosis and extensive areas of necrosis are seen. Areas of calcification are also seen. Tumor involves the lamina propria and muscle.

CASE PRESENTATION 3

A 60-year-old male reported with hematuria and backpain for the last three weeks. He had no other significant signs or symptoms and had good physical performance with an ECOG score of 1. Baseline hematological investigations were normal except except urinalysis which showed hematuria. Ultrasound was done which as well revealed an intravesical mass.

CC-BY 4.0 Licensed

CT Chest, Abdomen and Pelvis (with contrast) was done which showed irregular and thickened bladder wall with large mass 4.7 x 5.2 x 3.8cm arising from the anterior wall of bladder. Air foci also noted within the lumen, with enlarged prostate.

Cystoscopy and TURBT were planned after which the tumor specimen was sent for biopsy. Histopathological review of biopsy showed dispersive sheets of moderately enlarged malignant cells with high nuclear to cytoplasmic ratio, fine stippled chromatin and few prominent nucleoli. Focal necrosis was also present. An extensive panel of immunohistochemical stains was done to determine the lineage of tumor cells. GATA3 (marker of urothelial carcinoma), NKX3.1 (marker of prostatic adenocarcinoma), Cytokeratin (for metastatic carcinoma), LCA (for lymphoid neoplasms), CD20 (for B-cell lymphoid neoplasms), CD 30 (for T-cell lymphoid neoplasms), CD138 (for plasma cell tumors), OCT 4 (for germ cell tumor), SOX10 (for neural and melanotic neoplasms) and Desmin, myogenin (for rhabdomyosarcoma) were all negative. Only Synaptophysin (strong membranous staining) and CAM5.2 (focal and patchy dot like staining) were positive, confirming the diagnosis of muscle invasive neuroendocrine carcinoma.

It was decided for the patient in multidisciplinary meeting to undergo NC (cisplatin based) followed by RC if the patient is fit for surgery. Four cycles of cisplatin/etoposide NC were given and were uneventful. After three months of NC, patient was assessed again and deemed fit for surgery. Radical cystectomy (RC) with pelvic lymphadenectomy and urinary diversion was planned and done, with clear surgical margins and no lymph node involvement seen on subsequent histopathology. CT Scans were done on follow up visit at 6 months and showed no residual tumor or recurrence.

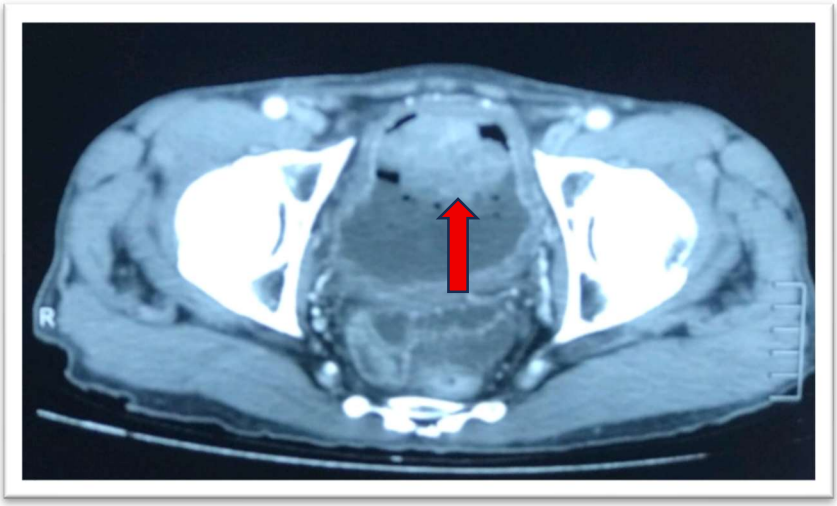

Figure 5 Show axial view of contrast enhanced CT scan of abdomen and pelvis showing, an irregular and thickened bladder wall with large mass 4.7 x 5.2 x 3.8cm arising from the anterior wall of bladder. Air foci also noted within the lumen as pointed by the red arrow

CC-BY 4.0 Licensed

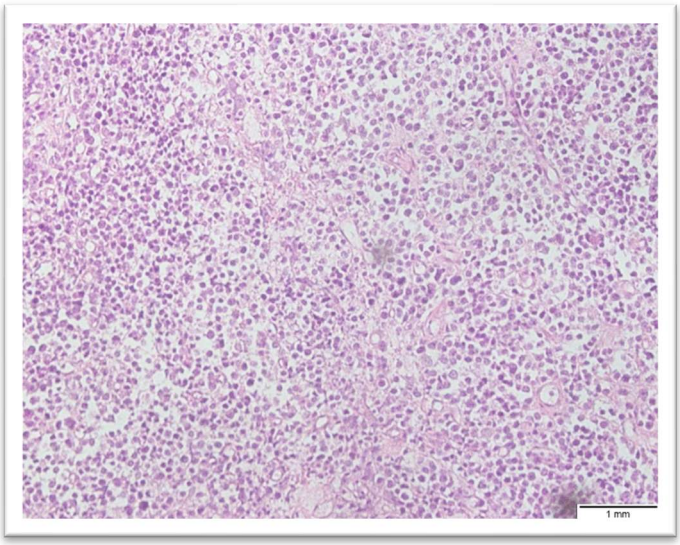

Figure 6 Shows microscopic image of H&E staining of tumor specimen at 20x magnification, consistent with small cell neuroendocrine carcinoma.

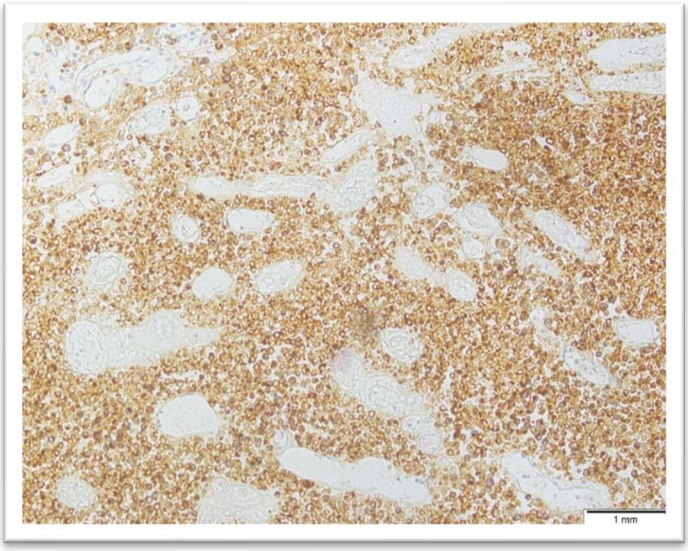

Figure 8 Shows microscopic image of synaptophysin staining at 20x magnification.

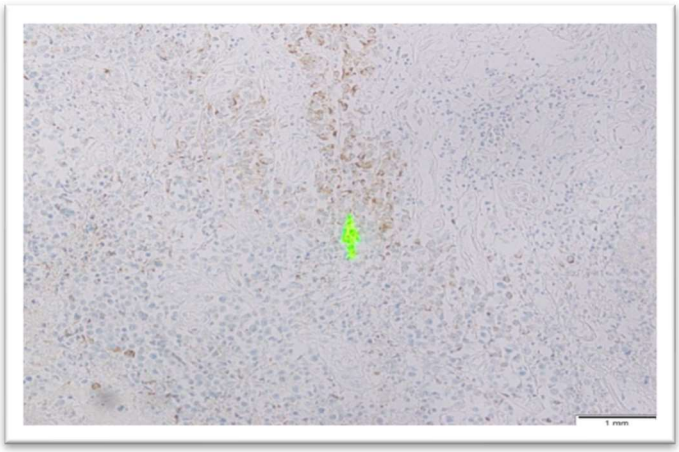

Figure 7 Shows microscopic image of CAM5.2 positive specimen staining at 20x magnification.

DISCUSSION

Neoadjuvant chemotherapy (NC) followed by radical cystectomy (RC) is a highly effective treatment strategy for SNECUB, a rare and aggressive malignancy characterized by a high likelihood of early metastasis and poor prognosis [4]. The rationale for this approach is supported by both clinical evidence and established treatment guidelines. NC, particularly with cisplatin-based regimens such as cisplatin and etoposide, targets micrometastatic disease early, reducing the likelihood of systemic progression. Studies have demonstrated that NC significantly improves overall survival (OS) and increases the likelihood of achieving pathologic downstaging to non-muscle-invasive disease (≤pT1N0), which is associated with better surgical outcomes [5]. For example, data from the National Cancer Database indicate that patients with neuroendocrine histology who received NC had a 51% reduction in mortality risk compared to those who underwent RC alone, highlighting the survival benefit of systemic therapy prior to surgery [6].

Radical cystectomy remains the cornerstone of local control for SNECUB, as surgery alone is insufficient to address the systemic nature of this disease. However, when combined with NC, RC achieves superior outcomes by enabling

CC-BY 4.0 Licensed

margin-negative resections in a down staged tumor. NC also reduces rates of non-organ confined disease at the time of surgery, as evidenced by an odds ratio of 0.16 for non-organ confined disease in patients treated with NC compared to surgery alone [7]. SNECUB shares molecular and clinical similarities with small-cell lung cancer, where cisplatin-etoposide regimens are standard due to high chemosensitivity [8]. Importantly, guidelines, including those from the National Comprehensive Cancer Network (NCCN) and European Association of Urology (EAU), strongly recommend neoadjuvant platinum-based chemotherapy for all patients with muscle-invasive bladder cancers, including those with neuroendocrine histology [9,10].

While adjuvant chemotherapy has been considered an alternative to NC, it is associated with delayed systemic treatment initiation and poorer survival outcomes compared to neoadjuvant approaches. In addition, surgery-first strategies risk missing the therapeutic window for patients who may not recover sufficiently postoperatively to tolerate chemotherapy. Therefore, NC prior to RC ensures that patients receive systemic therapy upfront while maintaining their eligibility for curative surgery [5].

CONCLUSION

Neoadjuvant cisplatin–etoposide chemotherapy followed by radical cystectomy offers the best chance for prolonged survival in localized SNECUB by exploiting the tumor's chemosensitivity and reducing metastatic risk. Despite the lack of standardized guidelines, current evidence supports this multimodal approach as the cornerstone of treatment. Future studies should evaluate optimized neoadjuvant regimens and the role of immunotherapy.

ACKNOWLEDGEMENTS

We acknowledge Hira Yaqub from department of pathology, Shaukat Khanum Memorial Cancer Hospital and Research Centre, Lahore, for providing the histopathology pictures.

ETHICAL APPROVAL

Ethical approval to report this case series was obtained from Research and Ethical Committee bearing approval number 549/chairman/R&E/Committee/IKD

FUNDING

This case series was not funded by any person or institution.

DECLARATION OF COMPETING INTEREST

The authors have no conflicts of interest to disclose in relation to this work.

CONSENT

Written informed consent was obtained from all the patients for publication of this case series and accompanying images. A copy of the written consent is available on request.

CONTRIBUTORSHIP

MK and AH drafted the manuscript. RAK supervised the work, and NK critically reviewed the manuscript. All authors approved the final manuscript for publication.

REFERENCES

1. Rico EJG, Polledo LEO, Pellejero AS, Valdés SV, Fernandez IM. Small-cell neuroendocrine tumor of the bladder: Unexpected long-term survival with carboplatin-etoposide therapy in a patient with metastatic stage disease. Urol Ann. 2023 Jul-Sep;15(3):331-333. doi: 10.4103/ua.ua_106_22. Epub 2023 Jul 17. PMID: 37664100; PMCID: PMC10471807.
2. Lu, J., Zhou, J., Liu, Y. et al. Treatment and survival of non-metastatic small cell carcinoma of the bladder from multiple centers in China. Sci Rep 14, 24652 (2024).

CC-BY 4.0 Licensed

3. Masood B, Iqbal N, Iqbal W, Masood Y, Akbar MK, Mamoon N. Small-cell neuroendocrine carcinoma of the urinary bladder: A case report. Int J Health Sci (Qassim). 2020 Mar-Apr;14(2):53-55. PMID: 32206060; PMCID: PMC7069666.
4. Vetterlein MW, Wankowicz SAM, Seisen T, Lander R, Löppenberg B, Chun FK, Menon M, Sun M, Barletta JA, Choueiri TK, Bellmunt J, Trinh QD, Preston MA. Neoadjuvant chemotherapy prior to radical cystectomy for muscle-invasive bladder cancer with variant histology. Cancer. 2017 Nov 15;123(22):4346-4355. doi: 10.1002/cncr.30907. Epub 2017 Jul 25. PMID: 28743155.
5. Sawasdee A, Tanthanuch M, Bejrananda T. Neoadjuvant versus Adjuvant Chemotherapy in Patients with Resectable Muscle-Invasive Bladder Cancer. Asian Pac J Cancer Prev. 2022 Nov 1;23(11):3641-3647. doi: 10.31557/APJCP.2022.23.11.3641. PMID: 36444575; PMCID: PMC9930955.
6. Chu CE, Iyer G, Bochner BH. Neoadjuvant Systemic Therapies in Bladder Cancer. Frontiers in Urology [Internet]. 2022;2. Available from: https://www.frontiersin.org/journals/urology/articles/10.3389/fruro.2022.890761
7. Witjes JA, Bruins HM, Cathomas R, et al. European association of urology guidelines on muscle-invasive and metastatic bladder cancer: summary of the 2020 guidelines. Eur Urol. 2021;79(1):82–104
8. Bray F, Ferlay J, Soerjomataram I, et al. Global cancer statistics 2018: GLOBOCAN estimates of incidence and mortality worldwide for 36 cancers in 185 countries. CA Cancer J Clin. 2018;68(6):394–424
9. Teoh JYC, Huang J, Ko WYK, et al. Global trends of bladder cancer incidence and mortality, and their associations with tobacco use and gross domestic product per capita. Eur Urol. 2020;78(6):1–11.
10. Yin M, Joshi M, Meijer RP, Glantz M, Holder S, Harvey HA, Kaag M, Fransen van de Putte EE, Horenblas S, Drabick JJ. Neoadjuvant Chemotherapy for Muscle-Invasive Bladder Cancer: A Systematic Review and Two-Step Meta-Analysis. Oncologist. 2016 Jun;21(6):708-15. doi: 10.1634/theoncologist.2015-0440. Epub 2016 Apr 6. PMID: 27053504; PMCID: PMC4912364.

CITE THIS ARTICLE:

- **APA (7th edition):** Khan, M., Khan, N., Haseeb, A., & Khan, R. A. (2026). Outcomes of multimodal therapy for bladder neuroendocrine carcinoma: A case series. *The Operating Room Global Journal (TORGJ), 2*(4), 160–167. https://doi.org/10.64573/torgj2610005
- **Harvard**: Khan, M., Khan, N., Haseeb, A. and Khan, R.A. (2026) 'Outcomes of multimodal therapy for bladder neuroendocrine carcinoma: A case series', *The Operating Room Global Journal (TORGJ)*, 2(4), pp. 160–167. Available at: https://doi.org/10.64573/torgj2610005
- **Vancouver**: Khan M, Khan N, Haseeb A, Khan RA. Outcomes of multimodal therapy for bladder neuroendocrine carcinoma: a case series. *The Operating Room Global Journal (TORGJ).* 2026 Nov 22;2(4):160–167. https://doi.org/10.64573/torgj2610005
- **MLA (9th edition)**: Khan, Maaz, et al. "Outcomes of Multimodal Therapy for Bladder Neuroendocrine Carcinoma: A Case Series." *The Operating Room Global Journal (TORGJ)*, vol. 2, no. 4, 22 Nov. 2026, pp. 160–167. https://doi.org/10.64573/torgj2610005
- **Chicago (Author-Date)**: Khan, Maaz, Nasir Khan, Abdul Haseeb, and Riaz Ahmed Khan. 2026. "Outcomes of Multimodal Therapy for Bladder Neuroendocrine Carcinoma: A Case Series." *The Operating Room Global Journal (TORGJ)* 2 (4): 160–167. https://doi.org/10.64573/torgj2610005

CC-BY 4.0 Licensed