



The Operating Room Global Journal (TORGJ)

<https://torgjournal.org/>

ISSN: 3105-3262



An Unsuspected Case of Hirschsprung Disease in an Adolescent: A Case Report.

Yirgalem Teklebirhan Gebreziher^{1,4*}, Feven Mekonen Tadesse¹, Hadush Tesfay Negash¹, Berihu Tadishu Gebre², Seare Halefom Kahsay¹, Ruta Mehari Tafere³

¹Department of Pediatric Surgery, Ayder Comprehensive Specialized Hospital, Mekelle University, Ethiopia.

²Department of Radiology, Ayder Comprehensive Specialized Hospital, Mekelle University, Ethiopia.

³Department of Internal Medicine, School of Medicine, College of Health Sciences, Aksum University, Tigray, Ethiopia.

⁴The Operating Room Global (TORG).

ABSTRACT

*Corresponding Author:

Yirgalem Teklebirhan Gebreziher

yirgalemtek1@gmail.com

Declaration:

Authors' Contribution: Equal contributions.

Conflict of Interest: No conflict of interest.

Funding: No funding received by the authors.

Article History:

Received: 28-12-2025

Accepted: 11-01-2026

Available Online: 14-01-2026

QR access this Article



Introduction: Hirschsprung's disease, a congenital disorder, is characterized by the absence of ganglion cells in the Meissner's plexus of the submucosa and Auerbach's plexus of the muscularis. Notably, late presentation is uncommon, with 95% of cases being diagnosed in infants younger than one year of age.

Case presentation: 15-year-old Black female patient presented to our hospital with the complaint of failure to pass feces of 5 days duration associated with abdominal distention. From an early age, she experienced persistent constipation and abdominal distention, leading to multiple admissions to local health centers for enema treatment. Oral laxatives were also prescribed, but they only provided temporary relief of her symptoms.

Clinical findings and investigations: Abdominal x-ray showed significantly dilated bowel loops with fecal loading. Barium enema showed a transition zone at the proximal one-third of the rectum with reversed rectosigmoid ratio.

Intervention and outcome: Rectal biopsy confirmed the diagnosis. Decompressive colostomy was done followed by soave pull through three months later. The patient is doing well during postoperative follow-up.

Conclusion: Adolescent patients with a history of childhood-onset constipation should be evaluated for the possibility of undiagnosed Hirschsprung's disease. Treating this condition can significantly enhance the patient's quality of life.

Keywords: Adult; Case report; Congenital; Constipation.

INTRODUCTION

Hirschsprung's disease is a congenital disorder characterized by the absence of ganglion cells in the Meissner's plexus of the submucosa and Auerbach's plexus of the muscularis (1). Hirschsprung's disease occurs in approximately 1 out of every 5,000 live births (2). The diagnosis is typically made before the age of 1 month in 65% of the total cases, and before the age of 1 year in 95% of the total cases. However, in rare cases, the condition may not be detected until the adolescent or adult years (3). This report presents a rare case of chronic constipation in an adolescent who was later diagnosed with Hirschsprung's disease and underwent a Soave pull-through procedure. This case report has been reported in line with the SCARE Criteria (4).

CASE PRESENTATION

15-year-old Black female patient presented to our hospital with the complaint of failure to pass feces of 5 days duration associated with abdominal distention. Since childhood, she had a history of constipation and abdominal distension, for which she was repeatedly admitted to local health centers and treated with enemas and oral laxatives. This provided only temporary relief of her symptoms. The timing of her first passage of meconium was unknown. On physical examination, the patient appeared chronically ill, wasted, and had significant abdominal distension. Rectal exam revealed loose stool with normal sphincter tone.

Baseline investigations, such as a complete blood count, serum electrolytes, and thyroid function tests, were all within normal limits. An abdominal X-ray revealed significantly dilated bowel loops with fecal loading (Fig 1). The barium enema revealed a transition zone in the proximal one-third of the rectum, with a reversed rectosigmoid ratio, which was suggestive of Hirschsprung's disease (Fig 2).

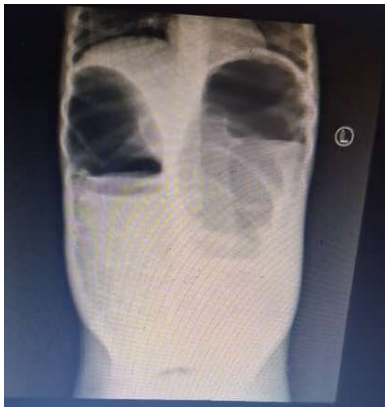

Figure 1: Abdominal x-ray showing significantly distended large bowel.

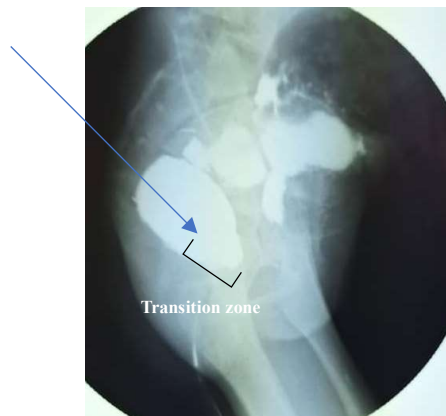


Figure 2: Contrast barium (oblique view).

The patient was prepared, and the abdomen was surgically explored through a left lower transverse incision, based on the clinical impression of large bowel obstruction secondary to an ultra-short segment of Hirschsprung's disease. Intraoperative findings revealed a transition zone at the rectosigmoid junction, accompanied by significant dilatation of the proximal colon (figure 3). A diverting decompressive sigmoid loop colostomy was performed, and tissue samples from the stoma and rectum were obtained and submitted for histopathological evaluation. The histopathological findings confirmed the presence of an aganglionic rectum and a ganglionated colostomy site.

Three months later, the patient underwent a Soave pull-through procedure. The postoperative course was uneventful. At the 6-month follow-up, she reported a dramatic improvement in her bowel function and experienced rapid weight gain.

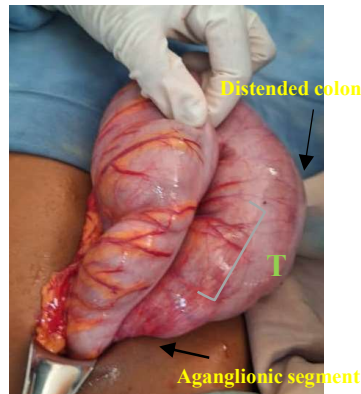


Figure 3: intraoperative picture

DISCUSSION

Hirschsprung's disease is characterized by the complete absence of ganglion cells within the colonic wall, resulting in an absent recto-anal inhibitory reflex (2). Hirschsprung's disease is a major cause of intestinal obstruction in infants. In over 90% of cases, diagnosis and treatment are carried out within the first 5 years of life. In contrast, Hirschsprung's disease in adults accounts for approximately 5% of cases and is often mistaken for chronic constipation (5).

Hirschsprung's disease is classified into four categories based on the length of the aganglionic segment: short (distal sigmoid colon and rectum), long (distal sigmoid colon and rectum to splenic flexure), total colonic aganglionosis (entire colon), and ultra-short (distal rectum and anal canal). Hirschsprung's disease in adults typically presents as the short or ultra-short form, with relatively mild symptoms, especially early in life (6).

When Hirschsprung's disease is clinically suspected, imaging studies, anal manometry, and full-thickness rectal biopsies are typically performed to confirm the diagnosis (2). A plain abdominal radiograph is typically the first diagnostic step. It may demonstrate a grossly distended large bowel, with a possible absence of stool in the distal colon or rectum. Additionally, a contrast enema can reveal a transition zone between the distal aganglionic bowel segment and the distended proximal ganglionated bowel, a finding considered the most accurate radiologic feature of Hirschsprung's disease (7). Definitive diagnosis of Hirschsprung's disease relies on a rectal biopsy, which reveals the absence of ganglion cells in the myenteric plexus and hypertrophy of the nerve endings (8).

The treatment of Hirschsprung disease is surgical. The principles of the operation are to remove the aganglionic colon and connect the normally innervated bowel just above the anus, at a level which prevents further functional obstruction, but at the same time preserves fecal continence. The definitive surgical intervention may be carried out in a single-stage or multi-stage approach. A stoma may still be the appropriate approach for children with severe enterocolitis, extensive dilatation of the proximal bowel, total colonic aganglionosis, or limited pathology support (9).

In cases of undiagnosed Hirschsprung's disease, patients often experience severe constipation from early childhood, and the colon proximal to the aganglionic bowel tends to be severely dilated. This can complicate surgical dissection and

create incongruence during anastomosis, making a one-stage pull-through procedure less effective in older children compared to infants. Early postoperative complications, particularly anastomotic leakage, occur frequently in children with late-diagnosed HD. Therefore, a diverting stoma should be considered for these patients (10). In our case, given the unavailability of frozen section, the presence of malnutrition, and the massive bowel dilatation, we decided to perform a two-stage surgery with an initial diverting loop colostomy.

The surgical treatment of adult Hirschsprung's disease should account for the anatomical changes and the technical challenges of dissection encountered in adulthood. While numerous surgical approaches have been described for Hirschsprung's disease, four primary techniques - Swenson, Duhamel, Soave, and Lynn procedures - are most utilized (11). The Soave procedure involves stripping the rectal mucosa, while maintaining the muscular cuff of the rectum. A ganglionic segment of colon is then brought down, and a colo-anal anastomosis is performed (2). The Soave pull-through is the preferred surgical technique at our institution, favored by our experienced surgeons who have achieved excellent results with this approach.

CONCLUSION

Adolescent patients with a history of childhood-onset constipation should be evaluated for the possibility of undiagnosed Hirschsprung's disease. Treating this condition can significantly enhance the patient's quality of life.

ACKNOWLEDGEMENTS

Not applicable.

ETHICAL APPROVAL

This type of study does not require any ethical approval by our institution.

FUNDING

This case report was not funded by any person or institution.

DECLARATION OF COMPETING INTEREST

The authors have no conflicts of interest to disclose in relation to this work.

CONSENT

Written informed consent was obtained from the patient's mother for publication of this case report and accompanying images. A copy of the written consent is available on request.

REFERENCES

1. Rahardjo TM, Nurzaman YA, Natalia J, Hapdijaya I, Devina L, Andrianto H, Mahardhika JC. Adult Hirschsprung's disease presenting as chronic constipation: a case report. *J Med Case Rep*. 2023 Jul 5;17(1):308. doi: 10.1186/s13256-023-03986-y. PMID: 37403154; PMCID: PMC10320872.
2. A.M. Holschneider, P. Puri, *Hirschsprung's Disease and Allied Disorders*, 2nd ed., Harwood Academic Publishers, Amsterdam, 2000.

3. Howsawi A, Bamefeh H, Al Jadaan S, et al. Clinicopathological characteristics of Hirschsprung's disease with emphasis on diagnosis and management: a single-center study in the Kingdom of Saudi Arabia. *Glob Pediatr Health*. 2019. <https://doi.org/10.1177/2333794X19848865>.
4. Sohrabi C, Mathew G, Maria N, Kerwan A, Franchi T, Agha RA. The SCARE 2023 guideline: updating consensus Surgical Case Report (SCARE) guidelines. *Int J Surg Lond Engl*. 2023;109(5):1136.
5. Bakari AA, Gali BM, Ibrahim AG, Nggada HA, Ali N, Dogo D, Abubakar AM. Congenital aganglionic megacolon in Nigerian adults: two case reports and review of the literature. *Niger J Clin Pract*. 2011 Apr-Jun;14(2):249-52. doi: 10.4103/1119-3077.84032. PMID: 21860150.
6. Agustina K, Margiani NN, Anandasari PPY, Mahastuti NM. Constipation that needs attention: late Hirschsprung disease. *Intisari Sains Medis*. 2021;12(1):64-7
7. Vlok SSC, Moore SW, Schubert PT, Pitcher RD. Accuracy of colonic mucosal patterns at contrast enema for diagnosis of Hirschsprung disease. *Pediatr Radiol*. 2020;50:810-6. <https://doi.org/10.1007/s00247-020-04631-2>.
8. Miyamoto M, Egami K, Maeda S, Ohkawa K, Tanaka N, Uchida E et al. Hirschsprung's disease in adults: report of a case and review of the literature. *J Nippon Med Sch*. 2005 Apr;72(2): 113-20.
9. Jacob C. Langer, Surgical approach to Hirschsprung disease, *Seminars in Pediatric Surgery*, Volume 31, Issue 2, 2022, 151156, ISSN 1055-8586, <https://doi.org/10.1016/j.sempedsurg.2022.151156>.
10. Stensrud, K. J., Emblem, R., & Bjørnland, K. (2012). Late diagnosis of Hirschsprung disease—patient characteristics and results. *Journal of Pediatric Surgery*, 47(10), 1874-1879. doi:10.1016/j.jpedsurg.2012.04.022 (<https://doi.org/10.1016/j.jpedsurg.2012.04.022>).
11. Adamou H, Amadou Magagi I, Habou O, Adakal O, Aboulaye MB, Robnodji A, James Didier L, Sani R, Abarchi H. Diagnosis and surgical approach of adult Hirschsprung's disease: about two observations and review of the literature – case series. *Annals of Medicine and Surgery (Lond)*. 2019 Oct 25;48:59-64. doi:10.1016/j.amsu.2019.10.017.

CITE THIS MANUSCRIPT

- **APA (7th edition):** Gebreziher, Y. T., Tadesse, F. M., Negash, H. T., Gebre, B. T., Kahsay, S. H., & Tafere, R. M. (2026, January 14). *An unsuspected case of Hirschsprung disease in an adolescent: A case report. The Operating Room Global Journal (TORGJ)*, 2(1). <https://doi.org/10.64573/torgj2512007>
- **Harvard:** Gebreziher, Y.T., Tadesse, F.M., Negash, H.T., Gebre, B.T., Kahsay, S.H. and Tafere, R.M., 2026. An unsuspected case of Hirschsprung disease in an adolescent: A case report. *The Operating Room Global Journal (TORGJ)*, 2(1). Published 14 January. Available at: <https://doi.org/10.64573/torgj2512007>
- **Vancouver:** Gebreziher YT, Tadesse FM, Negash HT, Gebre BT, Kahsay SH, Tafere RM. An unsuspected case of Hirschsprung disease in an adolescent: A case report. *The Operating Room Global Journal (TORGJ)*. 2026 Jan 14;2(1). <https://doi.org/10.64573/torgj2512007>
- **MLA (9th edition):** Gebreziher, Yirgalem Teklebirhan, et al. "An Unsuspected Case of Hirschsprung Disease in an Adolescent: A Case Report." *The Operating Room Global Journal (TORGJ)*, vol. 2, no. 1, 14 Jan. 2026, <https://doi.org/10.64573/torgj2512007>
- **Chicago (Author-Date):** Gebreziher, Yirgalem Teklebirhan, Feven Mekonen Tadesse, Hadush Tesfay Negash, Berihu Tadishu Gebre, Seare Halefom Kahsay, and Ruta Mehari Tafere. 2026. "An Unsuspected Case of Hirschsprung Disease in an Adolescent: A Case Report." *The Operating Room Global Journal (TORGJ)* 2 (1), January 14. <https://doi.org/10.64573/torgj2512007>